

**Rosie Callaghan,**  
Tissue Viability Nurse Specialist, Worcester Health and Care Trust, Worcester

### Background

A 26-year-old female who had a breast abscess was visiting a practice nurse for dressing changes and was able to continue to work in the retail industry. The patient was fit and well, with no comorbidities or relevant medical history. After the breast abscess developed, it was surgically drained. Although, initial progress was good, the wound became stalled. The patient was referred to the tissue viability (TV) team at 18 months due to non-healing of the abscess.

On referral to the TV team, the abscess measured 1cm long x 1cm wide x 5cm deep. It was not painful and the wound bed was epithelialising. There was slight malodour and daily dressing changes were required to manage the moderate level of serosanguinous exudate. The patient had been on antibiotics on and off for 12 months, including at the time of referral. The TV team consulted with a microbiologist, who suggested stopping the antibiotics and cleansing the wound daily for a week with an octenidine-containing solution. As the patient was independent and active, and exudate levels were moderate, the NANOVA™ Therapy System was initiated 1 week later to promote wound healing. Dressing change was scheduled for 3 days later.

**Review 1:** At day 3, the wound had not changed in size, measuring 1cm x 1cm, but depth had reduced to 3cm (40% reduction from baseline), and the wound bed was now 100% granulating. The patient continued to have no pain and malodour had resolved. Exudate levels were still moderate, but there was no leakage; the patient reported being 'pleasantly surprised' that it had coped where previous dressings had not. Periwound skin was healthy. Application, set-up and use of the NANOVA™ Therapy System was rated as 'very easy' — it took 5 minutes from start to finish, and only two depressions of the pump were required to achieve negative pressure. The patient reported high levels of comfort during wear. The NANOVA™ Therapy System was continued, with dressing changes scheduled every 3 days.

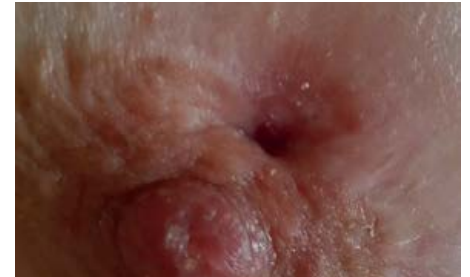**Review 2:** At day 6, the wound size remained unchanged. However, exudate levels were noticeably lower, and periwound skin remained healthy. Patient comfort and clinician ease of use were both highly rated. Because the wound was improving, NANOVA™ Therapy was continued, with changes every 3 days.

**Review 3:** Six days later, the wound still measured 1cm x 1cm, but depth had reduced to 2cm (60% reduction in wound depth from baseline). Exudate levels were still low, and surrounding skin remained healthy. Satisfaction with comfort and ease of use remained high, and the patient reported being 'so happy' that the wound appeared to be healing after such a long time. NANOVA™ Therapy was continued with changes every 3 days.

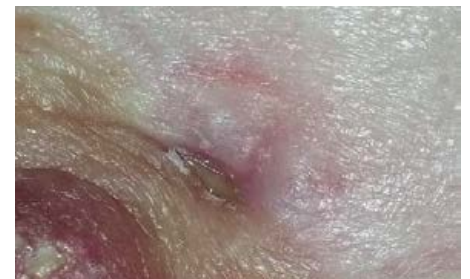**Review 4:** One week later (week 3), the wound had continued to decrease in size, now measuring 0.5cm x 0.5cm (a 75% reduction in wound area from baseline) x 0.5cm deep (a 90% reduction in wound depth from baseline). The wound bed was epithelialising, exudate levels were low, and periwound skin remained healthy. The patient reported high levels of comfort during wear with no reports of wound-related pain, which had a huge impact on the patient's wellbeing. All parameters for ease of set-up, application and use were rated 'very easy'. The NANOVA™ Therapy System was discontinued as all treatment goals had been met and the patient was given a simple wound dressing.

As with any case study, the results and outcomes should not be interpreted as a guarantee or warranty of similar results. Individual results may vary depending on the patient's circumstances and condition.

Reprinted with the permission of *Wounds UK*. This case study was originally published in a Round Table Discussion Document: Using NANOVA™ Therapy System in Practice: a round table discussion. London: *Wounds UK*. 2014.



At the start of therapy



At week 3

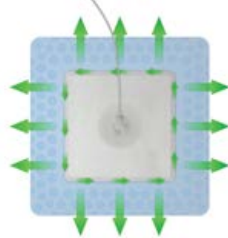
### Summary

Breast abscess of 18 months' duration in a young active woman  
60% reduction in wound depth by 12 days  
Difficult-to-dress area with almost complete healing achieved at week 3 with the NANOVA™ Therapy System

The patient reported being 'so happy' that the wound appeared to be healing after such a long time and found the dressing comfortable to wear.

### 1 Sealing the Dressing

- After application, smooth the silicone around the pad, working outward to the edge of the dressing.
- If you observe a crease in the adhesive border, lift and reseal rather than trying to iron out the wrinkle.



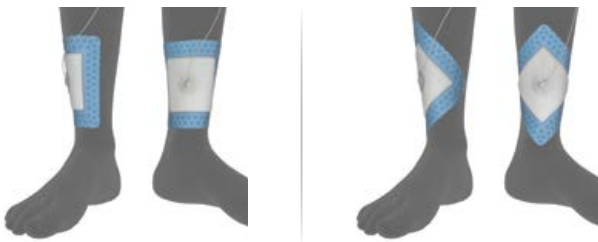### 2 Exudate & Dressing Positioning

- When managing wounds on dependent anatomy, fluid absorption capacity can be optimised by placing the dressing so there is more absorptive pad below rather than above the wound.
- Fluid is retained within the absorptive core of the dressing to minimise the potential for maceration.



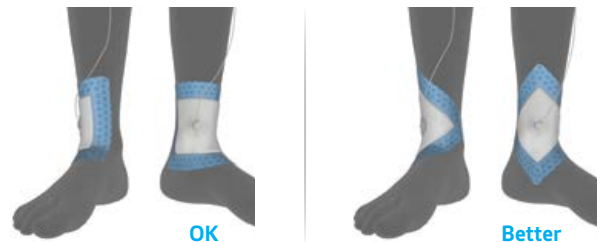### 3 Anatomical Contours

- Pay attention to anatomical contours.
- Positioning the dressing as a square on compound curves can transfer tension to the dressing border. This can be avoided and conformity improved if the dressing is rotated.




### 4 Joints

- When applying the dressing close to joints, care should be taken to ensure the dressing pad will not be creased in a tissue fold. Orient the dressing to minimise the amount of dressing pad or border that is extended over joints. On lower leg wounds this includes:
  - The malleolus.
  - The flexion point between the leg and dorsum of the foot.
  - Achilles tendon to the rear.



### 5 Skin Folds & Depressions

- Stability of anatomy is not always obvious. Observe movement of the wound site before placing the dressing (patient standing vs. supine position).
- Where practical, place the port above or below a tissue fold. Placing the port over a skin fold or tissue depression may increase tension on the adhesive border which could lead to loss of seal. Careful placement may also be more comfortable.



#### In Summary:

- Consider the anatomy, how the dressing will conform, and rotate the dressing when applying to areas that present compound curves.
- Orient the dressing to minimise the amount of pad or adhesive border over joints, for example the ankle.
- Position the pressure transfer port above or below tissue crease lines and folds.
- When in doubt, have the patient sit or ambulate so you can observe movement at and around the wound site.
- Provided clinically appropriate, consider using a thin hydrocolloid or similar primary contact layer to bridge voids under the adhesive border.
- It is okay to use clinically appropriate secondary fixation if deemed essential to maintaining an effective seal.
- If the wound appears too large for the dressing, consider an alternative negative pressure system such as V.A.C.VIA™ or ACTIV.A.C.™ Therapy Systems.

#### Customer Contact Information

For questions regarding this product, supplies, or additional information about KCI products and services, please contact your Acclity sales authorized representative. Visit [kci-medical.com](http://kci-medical.com)

**NOTE:** Specific indications, contraindications, warnings, precautions and safety information exist for KCI products and therapies. Before use, clinicians must review all risk information and essential prescribing information which can be found in the NANOVA™ Therapy System Instructions for Use. This material is intended for healthcare professionals.

©2016 KCI Licensing, Inc. All rights reserved. All trademarks designated herein are proprietary to KCI Licensing, Inc., its affiliates and/or licensors. DSL#16-0203.SYX5422.OUS.CS2 (5/16)